

Retinal Imaging

Choroidal thinning: Alzheimer's disease and aging

João Paulo Cunha^{a,b,*}, Rita Proença^a, Arnaldo Dias-Santos^a, Diana Melancia^c, Rita Almeida^c, Helena Águas^c, Bruno Oliveira Santos^d, Marta Alves^e, Joana Ferreira^{a,b}, Ana Luísa Pupoila^{b,e,f}, Carlota Louro^b, António Castanheira-Dinis^g

^aDepartment of Ophthalmology, Central Lisbon Hospital Center, Lisbon, Portugal

^bNOVA Medical School, Universidade NOVA de Lisboa, Lisbon, Portugal

^cDepartment of Neurology, Central Lisbon Hospital Center, Lisbon, Portugal

^dCERIS-ICIST, Instituto Superior Tecnico, Lisbon University, Lisbon, Portugal

^eEpidemiology and Statistics Unit, Research Centre, Central Lisbon Hospital Center, Lisbon, Portugal

^fCEAUL (Center of Statistics and Applications), Lisbon University, Lisbon, Portugal

^gVisual Sciences Study Center, Faculty of Medicine, Lisbon University, Lisbon, Portugal

Abstract

Introduction: The purpose of this study was to measure and to compare macular choroidal thickness (CT) between patients with mild Alzheimer's disease (AD), patients without AD, and elderly patients.

Methods: CT was measured manually in 13 locations at 500- μ m intervals of a horizontal and a vertical section from the fovea. Linear regression models were used to analyze the data.

Results: Fifty patients with a diagnosis of mild AD (73.1 years), 152 patients without AD (71.03 years), and 50 elderly without AD (82.14 years) were included. In the AD patients, CT was significantly thinner in all 13 locations ($P < .001$ —comparing with age-match group), and comparing with the elderly group, a more pronounced difference was found in two locations temporal to the fovea.

Discussion: Patients with AD showed a significant choroidal thinning even when compared with elderly subjects. The reduction of CT may aid in the diagnoses of AD, probably reflecting the importance of vascular factors in their pathogenesis.

© 2017 The Authors. Published by Elsevier Inc. on behalf of the Alzheimer's Association. This is an open access article under the CC BY-NC-ND license (<http://creativecommons.org/licenses/by-nc-nd/4.0/>).

Keywords:

Alzheimer's disease; Aging; Choroidal thickness; Enhanced depth imaging; Spectral-domain optical coherence tomography; Alzheimer's choroidopathy

1. Introduction

Alzheimer's disease (AD) is the most common form of dementia and is a major global medical, social, and economic public health issue [1]. There has been a long-standing interest in determining whether vascular mechanisms contribute to the development of AD [2,3]. The earliest AD pathological change in the brain is the accumulation of amyloid β (A β) [4,5]. Microvascular amyloid deposition (amyloid angiopathy) [6], granulovacuolar degeneration, loss of neurons and white matter,

synapse loss, gliosis [7], inflammation, and oxidative damage are other pathological changes present in AD [4,8].

Accumulating evidence suggests that vascular factors, especially those affecting the cerebral microcirculation (e.g., hypertension, diabetes), play an important role in the pathogenesis of AD [9].

The retinal and cerebral small blood vessels share similar properties (embryological, anatomical, and physiological) such as blood brain and blood-retina barrier and nonanastomotic end arteries [10]. To our knowledge, the first study to demonstrate abnormalities in the retinal circulation of patients with AD was published by Berisha et al., where retinal hemodynamic data obtained in patients with mild or moderate AD showed a marked narrowing of the retinal venous blood column diameter, and a reduction in

*Corresponding author. Tel.: 003513136300.

E-mail address: cunha.oft@gmail.com

retinal blood flow rate compared with age-matched controls subjects [11].

The choroid is affected in many retinal diseases. Changes in choroidal homeostasis have been documented in early macular degeneration and in advanced aging [12,13]. Decreased choroidal vasculature thickness has been described in age-related macular degeneration [14], although it has not been observed universally. Some choroidal thinning occurs during normal aging and is seen specially in some patients in a condition referred to as age-related choroidal atrophy [15]. It has been demonstrated in mice and in transgenic mouse models of AD an age-dependent amyloid accumulation in the choroid vasculature. The atrophy of the choroid capillaries has been shown to occur with normal aging [16].

Historically, imaging of the choroid in patients was possible with indocyanine green angiography, where injection of this fluorescent dye and subsequent imaging of fluorescence allowed two-dimensional imaging of the choroid pattern and the existence of leakage and vessel wall abnormalities [17]. Since the first study of Spaide et al., measuring choroid by enhanced depth imaging (EDI) optical coherence tomography (OCT) [18], it took about 5 years for the first studies to be published using this technique to assess choroidal thickness (CT) in patients with AD. Choroidal thickness has shown to be reduced in patients with AD comparing with controls [19–21] as review by Cunha et al. [22].

The present study aimed to identify factors that could explain the differences between CT of patients with mild AD and patients without AD, after controlling for age. Knowing that this factor is highly associated with CT thinning, a third group of elderly subjects without AD was also considered with the purpose of comparing their CT with those of AD patients. To our knowledge, this is the first study to compare CT with spectral-domain OCT (SD-OCT) of AD patients with very old normal subjects.

2. Materials and methods

2.1. Subject groups

This cross-sectional observational study was conducted at the Ophthalmology and Neurology Departments of the Central Lisbon Hospital Center, between October 2014 and April 2016. Consecutive AD patients sent by the Neurology Department for ophthalmological screening were observed for inclusion/exclusion criteria. AD patients with age between 65 and 78 years old with normotensive eyes and with ability to understand the study were included.

The exclusion criteria were as follows: refractive error >5 diopters (D) and/or axial length >25 mm in the studied eye; known diagnosis of diabetic retinopathy or other retinal diseases; glaucoma or ocular hypertension; uveitis; neurodegenerative disease; significant media opacities that precluded fundus imaging. In addition, patients with another

relevant known neurological pathology, such as neurodegenerative diseases, other types of dementia, previous stroke, or uncertain/indeterminate diagnosis, were excluded.

Informed consent was obtained for all the patients and the study was approved by our Institutional Ethics Committee. The principles of the Declaration of Helsinki were respected.

Ultimately, 50 patients were recruited for the AD group (ADG) and 202 subjects for the two groups without AD: 152 age-matched patients for the first control group (CG1) and 50 subjects older than 78 years for the second control group (CG2). Subjects without AD were recruited from the Neurology department.

2.2. Study procedures

After a prescreening visit where demographic, background history, full ophthalmological examination with visual acuity, anterior segment examination, Goldmann applanation tonometry, indirect ophthalmoscopy, and ultrasonic biometry were recorded, patients were assigned to a specific study visit. In this study visit, the SD-OCT scan was performed. Randomly, one eye of each subject was used in this study.

2.2.1. Visual acuity

Best corrected distance visual acuity (BCVA) for each eye was measured using Snellen charts and converted to the logarithm of the minimum angle of resolution.

2.2.2. Intraocular pressure

Intraocular pressure (IOP) was measured before pupillary dilation with Goldmann applanation tonometry and taken the mean of 3 measurements.

2.2.3. Spectral-domain optical coherence tomography imaging

All eyes were examined with SD-OCT (*Spectralis Heidelberg Engineering*, Germany). OCT imaging technique consists in obtaining a macular square (20–20°) composed of 25 horizontal B-scans. All scans were performed in EDI mode to improve the quality of choroidal imaging according to the previously reported method [23]. The choroid was imaged by positioning the SD-OCT device close enough to the eye to obtain an inverted image. The profile scans were saved for analysis after automatic averaging 100 frames using the eye-tracking feature embedded in the device. All OCT examinations were performed at the same time of the day from 2 to 4 PM. The OCT images were obtained by one ophthalmologist (A.S.) and were assessed by another ophthalmologist (J.P.C.) independently of each other, masked to the patients' diagnosis. The CT was measured from the outer portion of the hyperreflective line corresponding to the retinal pigment epithelium to the hyporeflexive line or margin corresponding to the sclerochoroidal interface. These measurements were made in the subfoveal choroid and at 500- μ m

intervals from the fovea to 1500 μm nasal, 1500 μm temporal, 1500 μm superior, and 1500 μm inferior (13 locations; Fig. 1).

2.2.4. Mean arterial pressure

The blood pressure was measured in seated position by an automatic sphygmomanometer and systolic blood pressure (SBP) and diastolic blood pressure (DBP) were recorded. The mean arterial pressure (MAP) was calculated using the following formula:

$$\text{MAP} = \text{DBP} + 1/3(\text{SBP} - \text{DBP})$$

2.3. Statistical analysis

Demographics and clinical characteristics of patients were described with frequencies (percentages) and with mean (standard deviation [SD]) or with median and interquartile range (25th percentile to 75th percentile), as appropriate. Nonparametric chi-square test and Mann-Whitney test were applied.

Linear regression models were used to identify the variables which explain the variability of CT, considering the three groups. The variables gender, age, IOP, axial length, spherical equivalent, MAP, and BCVA were considered in this analysis. Those variables attaining a P -value $< .25$ in the univariable analysis were selected as candidates for the multivariable models. Normality assumption of the residuals was verified using Kolmogorov–Smirnov goodness-of-fit test with Lilliefors correction. To quantify the size of the difference between ADG and CG1, Cohen's d was used. Because of the problem of multiple testing, Bonferroni corrections were applied. A level of significance $\alpha = 0.05$ was considered. Data were analyzed using the Statistical Package for the

Social Science for Windows (IBM Corp. Released 2013. IBM SPSS Statistics for Windows, version 22.0. Armonk, NY: IBM Corp.)

3. Results

3.1. Patient demographics and clinical characteristics

A total of 50 patients with AD (16 males), 152 patients without AD (55 males), and 50 older subjects without AD (17 males) were included in this study.

The mean age was 73.1 (SD = 5.36) years in ADG, 71.0 (SD = 4.62) years in CG1, and 82.1 (SD = 3.67) years in CG2, with significant differences between ADG and CG1 ($P = .011$), and between ADG and CG2 ($P < .001$). Regarding gender, no significant differences were found between ADG and CG1 ($P = .591$) and between ADG and CG2 ($P = .832$).

The BCVA was significantly lower in patients of the ADG comparing with CG1 and CG2 ($P < .001$ and $P = .001$, respectively). Regarding the spherical equivalent, a significant difference was also found among ADG and CG2 ($P = .021$). No other significant differences were found between the groups (Table 1).

3.2. EDI-OCT

3.2.1. Choroidal thickness AD group versus control group 1

The detailed description of the CT of both groups is presented in Table 2. In all 13 locations, the differences were statistically significant ($P < .001$). Results of the univariable analysis of the remaining variables are shown in Supplementary Tables 1–4.

In the multivariable regression models, after adjusting for age, spherical equivalent, BCVA, IOP, axial length, and

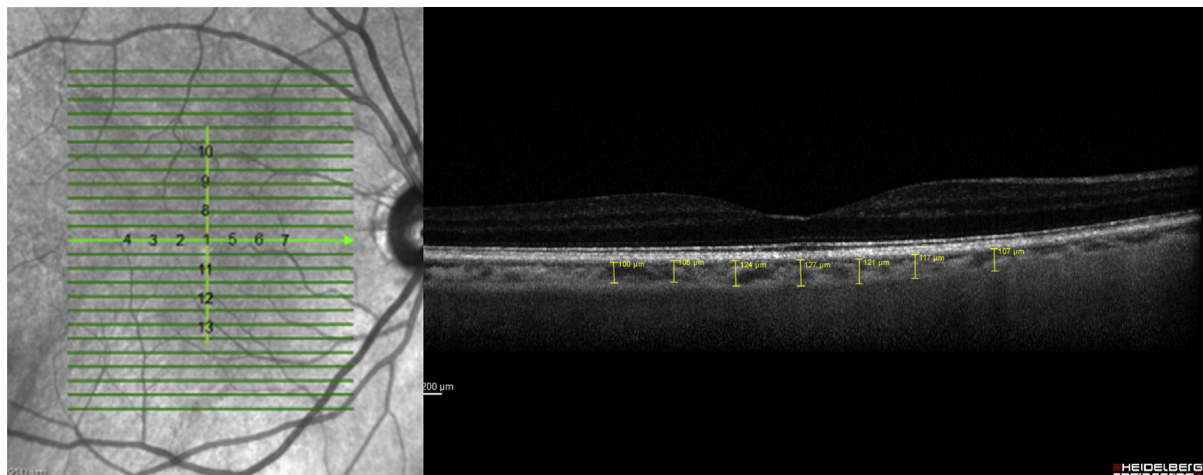


Fig. 1. Choroidal thickness. The measurements were made in the subfoveal choroid and at 500- μm intervals from the fovea to 1500 μm nasal, 1500 μm temporal, 1500 μm superior, and 1500 μm inferior (13 locations).

Table 1
Demographic and clinical characteristics of the patients by group

Variables	Alzheimer's group (n = 50)	Control group 1 (n = 152)	Control group 2 (n = 50)
Age (years)	73.1 (5.36)	71.0 (4.62)	82.1 (3.67)
Male sex, n (%)	16 (32)	55 (36)	17 (34)
BCVA (logMAR)	0.121 (0.153)	0.040 (0.073)	0.038 (0.066)
IOP–Goldmann (mm Hg)	15.52 (2.62)	14.72 (2.51)	14.54 (2.32)
Spherical equivalent (D)	0.995 (1.43)	0.700 (1.64)	0.267 (1.80)
Axial length (mm)	22.44 (0.91)	22.49 (0.99)	22.48 (0.96)
Mean arterial pressure (mm Hg)	98.91 (94.67–103.33)	97.87 (93.75–101.25)	97.84 (94.00–100.42)

Abbreviations: BCVA, best corrected visual acuity; logMAR, logarithm of the minimum angle of resolution; IOP, intraocular pressure; SD, standard deviation; IQR, interquartile range.

NOTE. Results are expressed as mean (SD) or median (IQR), as appropriate.

MAP, we identified significant differences in CT between the groups in all 13 locations (Table 3). In all locations, except at 500 and 1000 μm superior and 1000 μm inferior of the fovea, independently from the group, age was negatively associated with CT with a mean decrease between 15.5 and 28.4, for each 10 additional years. Spherical equivalent was also associated with CT in four locations, namely 1000 and 1500 μm nasal, 1500 μm superior, and 1500 μm inferior of the fovea. For each increase of 1 D in spherical equivalent value, the CT was thicker in ADG with increases between 5.3 and 7.2 μm (Table 3).

3.2.2. Choroidal thickness AD group versus control group 2

Despite a nonsignificant overall difference in CT, there was a general trend toward a thinning of CT in patients with AD compared to the very old subjects, with thicknesses varying from 137.60 to 179.50 μm and from 156.34 to 190.44 μm , respectively. After Bonferroni correction, no statistical differences were found between CT of ADG and CG2 for all locations. However, at locations 500 and 1000 μm temporal to the macula, a more pronounced difference between the two groups was found ($P = .032$ and $P = .037$, respectively). The detailed description of the CT of both groups is described in Table 4. Results of the univariable

analysis of the remaining variables are shown in Supplementary Table 5. No multivariable regression model was achieved.

4. Discussion

One of the most important problems in the early diagnosis of AD is the inability to directly visualize single-cell changes in real time in the brain. Fortunately, this is almost possible to achieve in the eye with OCT technology.

The choroid is a highly vascular structure, and similar to any microvasculature in the body, it is likely to undergo structural and functional alterations with increasing age. This generally involves a reduction in perfusion to the outer retina, which may have an impact on visual function. According to histological studies, the human subfoveal CT is approximately 194 μm at birth and decreases to approximately 80 μm by the age of 90 years [24].

The principal role of the choroid is to supply oxygen to the outer retina up to the level of the inner nuclear membrane and, therefore, the neurosensory retina in the foveal avascular zone derives blood from the choroid [17]. Vascular choroidal changes can therefore occur in patients with vascular risk factors as AD.

Table 2
Comparison of choroidal thickness (μm) between ADG and CG1 groups at 13 locations

Locations	Alzheimer's group (n = 50)	Control group 1 (n = 152)	P value	Effect size (Cohen's d)
Subfoveal central	169.02 (55.03)	253.18 (58.62)	<.001	1.48
Temporal 500 μm	163.26 (52.34)	242.39 (56.32)	<.001	1.46
Temporal 1000 μm	163.12 (50.31)	234.30 (52.13)	<.001	1.39
Temporal 1500 μm	170.76 (47.24)	230.81 (54.17)	<.001	1.18
Nasal 500 μm	156.64 (55.32)	234.76 (59.53)	<.001	1.36
Nasal 1000 μm	150.46 (58.18)	224.27 (60.09)	<.001	1.25
Nasal 1500 μm	137.60 (59.82)	213.30 (62.03)	<.001	1.24
Superior 500 μm	170.58 (57.95)	245.35 (54.99)	<.001	1.32
Superior 1000 μm	173.68 (59.32)	244.13 (53.51)	<.001	1.25
Superior 1500 μm	179.50 (60.09)	241.41 (53.74)	<.001	1.09
Inferior 500 μm	160.86 (65.91)	236.11 (61.36)	<.001	1.18
Inferior 1000 μm	159.66 (64.76)	232.53 (60.33)	<.001	1.16
Inferior 1500 μm	161.98 (74.56)	226.27 (65.19)	<.001	0.92

Abbreviations: ADG, Alzheimer's disease group; CG1, first control group; SD, standard deviation.

NOTE. Results are expressed as mean (SD); P-values were obtained by univariable linear regression models.

Table 3
Results of multivariable regression models—dependent variable: choroidal thickness

Model*	Coefficient estimate	P-value	95% confidence interval	
Dependent variable: choroidal thickness subfoveal central				
Alzheimer's group	-80.810	<.001	-99.528	-66.091
Age (years)	-16.963	.045	-33.559	-0.368
Dependent variable: choroidal thickness 500 µm temporal of the fovea				
Alzheimer's group	-75.582	<.001	-93.485	-57.680
Age (years)	-18.000	.026	-33.872	-2.127
Dependent variable: choroidal thickness 1000 µm temporal of the fovea				
Alzheimer's group	-68.118	<.001	-85.383	-50.853
Age (years)	-15.494	.047	-30.801	-0.187
Dependent variable: choroidal thickness 1500 µm temporal of the fovea				
Alzheimer's group	-56.817	<.001	-73.304	-40.330
Age (years)	-16.378	.028	-30.995	-1.761
Dependent variable: choroidal thickness 500 µm nasal of the fovea				
Alzheimer's group	-74.206	<.001	-93.108	-55.304
Age (years)	-19.848	.021	-36.606	-3.089
Dependent variable: choroidal thickness 1000 µm nasal of the fovea				
Alzheimer's group	-70.080	<.001	-88.938	-51.222
Age (years)	-28.399	.001	-45.154	-11.644
Spherical equivalent	6.422	.013	1.369	11.476
Dependent variable: choroidal thickness 1500 µm nasal of the fovea				
Alzheimer's group	-72.878	<.001	-92.412	-53.344
Age (years)	-24.992	.005	-42.348	-7.635
Spherical equivalent	7.242	.007	2.007	12.477
Dependent variable: choroidal thickness 1500 µm superior of the fovea				
Alzheimer's group	-60.019	<.001	-77.838	-42.199
Age (years)	-17.421	.031	-33.254	-1.588
Spherical equivalent	5.283	.030	0.508	10.059
Dependent variable: choroidal thickness 500 µm inferior of the fovea				
Alzheimer's group	-71.580	<.001	-91.832	-51.328
Age (years)	-18.570	.043	-36.525	-0.615
Dependent variable: choroidal thickness 1500 µm inferior of the fovea				
Alzheimer's group	-61.618	<.001	-83.369	-39.867
Age (years)	-22.626	.022	-41.951	-3.301
Spherical equivalent	6.144	.039	0.315	11.973

*Reference category: control group 1; age: for each increase of 10 years; P-values were obtained by linear regression models.

In vivo studies have demonstrated that CT varies topographically within the posterior pole and is inversely correlated with age. It decreases approximately 16 µm for each decade of life. A study reviewed 54 eyes and demonstrated that CT was thinnest nasally and thickest subfoveally [25,26]. It is possible to find different data from our literature. Shin et al. found an average thickness of the choroid of 285.9 (SD = 53.0) µm [26], thicker than the 186.1 (SD = 52.6) µm of our group of older subjects. The reason for this discrepancy is likely caused by the fact that Shin et al. measured the choroid as extending from Bruch's membrane to the sclera, whereas we only measured the choroid extending as far as the vessel walls closest to the sclera. Their population was also much younger (mean age 45.28 vs. 82.12 years old). Another Chinese study compares 70 patients older than 60 years with 140 younger patients, where mean CT of older than 60 years was 196.52 (SD = 74.42) µm, much thinner than that for subjects younger than 60 years [27] and very similar to our results

Table 4
Comparison of choroidal thickness (µm) between ADG and CG2 groups at 13 locations

Locations	Alzheimer's group (n = 50)	Control group 2 (n = 50)	P-value
Subfoveal central	169.02 (55.03)	189.58 (55.93)	.067
Temporal 500 µm	163.26 (52.34)	186.12 (52.59)	.032
Temporal 1000 µm	163.12 (50.31)	185.44 (54.96)	.037
Temporal 1500 µm	170.76 (47.24)	178.52 (53.89)	.446
Nasal 500 µm	156.64 (55.32)	172.48 (56.12)	.158
Nasal 1000 µm	150.46 (58.18)	166.06 (57.12)	.179
Nasal 1500 µm	137.60 (59.82)	156.34 (60.59)	.123
Superior 500 µm	170.58 (57.95)	186.40 (56.01)	.154
Superior 1000 µm	173.68 (59.32)	190.44 (56.38)	.151
Superior 1500 µm	179.50 (60.09)	189.50 (55.78)	.391
Inferior 500 µm	160.86 (65.91)	177.04 (55.51)	.187
Inferior 1000 µm	159.66 (64.76)	174.40 (62.30)	.249
Inferior 1500 µm	161.98 (74.56)	159.70 (60.63)	.867

Abbreviations: ADG, Alzheimer's disease group; CG2, second control group; SD, standard deviation.

NOTE. Results are expressed as mean (SD); P-values were obtained by univariable linear regression models.

if we keep in mind the rate of thinning of CT per year. According to several studies, the choroidal vasculature thickness decreases at rates ranging from 0.72 µm to 2.98 µm each year, as described by Wakatsuki et al. using swept-source OCT [25,28–31].

In addition, CT was found to be highly correlated with age, axial length, and refraction, emphasizing the importance of controlling for these variables when studying any patient population [32,33]. More interestingly, CT varied on a diurnal basis by as much as 33 µm (ranging from 8 to 65) in one study, suggesting that it can be a highly variable measure of choroidal vasculature and further emphasizing the need to develop novel approaches to reliably assess choroidal vascular health in vivo [33,34].

Patients with AD have an altered microvascular network in the retina (narrower retinal venules and a sparser and more tortuous retinal vessels) compared with matched controls [35–37]. The accumulation of Aβ and development of neurofibrillary tangles cause neurotoxicity, neuronal and synaptic loss, and vascular angiopathy [38]. The role of choroidal vasculature in the pathogenesis of AD is unknown, but the results in this study of choroidal thinning in patients with AD when compared with controls support previous results of others studies [19–21].

To our knowledge, this is the first study to compare CT with SD-OCT of AD patients with very old normal subjects.

In our study, we used EDI SD-OCT to compare CT in AD patients with two control groups. One eye per patient was selected and all examinations were performed at the same time of the day. In the multivariable analysis, after adjustment for gender, visual acuity, IOP, axial length, spherical equivalent, and MAP, the CT continues to be thinner in all locations. As in other studies [20,21], the central measurements have more significant differences. That is probably why in the comparison with the older

group a more pronounced difference was observed in 2 locations closer to the fovea: 500 and 1000 μm temporal to the fovea. This thinning of the choroid in AD patients may be related with choroidal atrophy secondary to amyloid angiopathy corresponding to the beginning of Alzheimer's choroidopathy beyond the age-related choroidal atrophy.

When we analyzed the pattern of CT in the control and AD groups, both had a normal distribution of CT [18], with a thicker superior quadrant than the inferior and a thicker temporal than nasal quadrant.

The models of multifactorial linear regression for the dependent variable CT support the importance of AD as a risk factor for choroidal atrophy besides aging.

Our study had some limitations. First, CT measurements were done manually. However, this manual technique already been proved to have a high intraobserver and interobserver reproducibility [39]. Second, the hydration status, that may affect the CT, was not taken into account. To this extent, we try to decrease any circadian variability by performing the measurements at the same time of the day and in the same location and environment.

The sensitivity of choroidal imaging in SD-OCT was improved through EDI-OCT, and we believe that optical coherence tomography angiography can provide important information through this three-dimensional volumetric imaging of the retinal and choroidal vasculature in future studies.

5. Conclusion

Patients with AD showed a choroidal thinning that was statistically significant in the 13 locations studied at 1.5 mm centered on the fovea. When compared with older subjects, there was a general tendency for the thinning of the choroid, with two central locations confirming a statistically significant difference. This thinning may reflect the importance of choroidal vascular factor in the pathogenesis of this disease and may aid in the diagnoses of "Alzheimer's choroidopathy" not related with age.

More clinical and tomographic studies should be conducted to suggest that "Alzheimer's choroidopathy" might precede, around 10 years, the age-related choroidal atrophy.

Acknowledgments

None of the authors have any conflict of interest to disclose.

Supplementary data

Supplementary data related to this article can be found at <http://dx.doi.org/10.1016/j.dadm.2017.03.004>.

RESEARCH IN CONTEXT

1. Systematic review: Alzheimer's disease is a prevalent, long-term progressive degenerative disorder with great social impact. There are a large number of publications using the optical coherence tomography showing that this technology is useful in early diagnosis of some structural alterations found in the retina and choroid, but some results are controversial.
2. Interpretation: In our study, we observed a choroidal thinning statistically significant in the 13 locations studied when compared with age-matched population. Even when compared with older subjects, there was a general tendency for the thinning of the choroid that may reflect the vascular importance in the pathogenesis of a possible "Alzheimer's choroidopathy" that might precede, more than 10 years, the age-related choroidal atrophy.
3. Future directions: We are studying the association between choroidal thinning and cerebral findings. Another study will compare "Alzheimer's choroidopathy" with other neurodegenerative eye diseases such as glaucoma and age macular degeneration using AngioOCT.

References

- [1] Alzheimer's Association. 2012 Alzheimer's disease facts and figures. *Alzheimers Dement* 2012;8:131-68.
- [2] de la Torre JC. Is Alzheimer's disease a neurodegenerative or a vascular disorder? Data, dogma, and dialectics. *Lancet Neurol* 2004; 3:184-90.
- [3] Kalaria RN. The role of cerebral ischemia in Alzheimer's disease. *Neurobiol Aging* 2000;21:321-30.
- [4] Selkoe DJ, Hardy J. The amyloid hypothesis of Alzheimer's disease at 25 years. *EMBO Mol Med* 2016;8:595-608.
- [5] Perl DP. *Neuropathology of Alzheimer's Disease*. Mt Sinai J Med 2010;77:32-42.
- [6] Ellis RJ. Cerebral amyloid angiopathy in the brains of patients with Alzheimer's disease: the CERAD experience, Part XV. *Neurology* 1996;46:1592-6.
- [7] Ingelsson M, Fukumoto H, Newell KL, Growdon JH, Hedley-Whyte ET, Frosch MP, et al. Early Abeta accumulation and progressive synaptic loss, gliosis, and tangle formation in AD brain. *Neurology* 2004;62:925-31.
- [8] Galasko D, Montine TJ. Biomarkers of oxidative damage and inflammation in Alzheimer's disease. *Biomark Med* 2010;4:27-36.
- [9] Kalaria RN, Akinyemi R, Ihara M. Does vascular pathology contribute to Alzheimer changes? *J Neurol Sci* 2012;322:141-7.

- [10] Patton N, Aslam T, MacGillivray J, Pattie A, Deary I, Dhillon B. Retinal vascular image analysis as a potential screening tool for cerebrovascular disease. *J Anat* 2005;206:318–48.
- [11] Berisha F, Feke GT, Trempe CL, Mcmeel JW, Schepens CL. Retinal abnormalities in early Alzheimer's disease. *Invest Ophthalmol Vis Sci* 2007;48:2285–9.
- [12] Mullins RF, Johnson MN, Faidley EA, Skeie JM. Choriocapillaris vascular dropout related to density of drusen in human eyes with early age-related macular degeneration. *Invest Ophthalmol Vis Sci* 2011;52:1606–12.
- [13] Mcleod DS, Grebe R, Bhutto I, Merges C, Baba T, Luty GA. Relationship between RPE and choriocapillaris in age-related macular degeneration. *Invest Ophthalmol Vis Sci* 2009;50:4982–91.
- [14] Jirattanasopa P, Ooto S, Nakata I, Tsujikawa A, Yamashiro K, Oishi A, et al. Choroidal thickness, vascular hyperpermeability, and complement factor H in age-related macular degeneration and polypoidal choroidal vasculopathy. *Invest Ophthalmol Vis Sci* 2012;53:3663–72.
- [15] Spaide RF. Age-related choroidal atrophy. *Am J Ophthalmol* 2009;147:801–10.
- [16] Gh A, Rosen RB. Combinations of techniques in imaging the retina with high resolution. *Prog Retin Eye Res* 2008;27:464–99.
- [17] Laviers H, Zambarakji H. Enhanced depth imaging-OCT of the choroid: a review of the current literature. *Graefes Arch Clin Exp Ophthalmol* 2014;252:1871–83.
- [18] Margolis R, Spaide RF. A pilot study of enhanced depth imaging optical coherence tomography of the choroid in normal eyes. *Am J Ophthalmol* 2009;147:811–5.
- [19] Gharbiya M, Trebbastoni A, Parisi F, Manganiello S. Choroidal thinning as a new finding in Alzheimer's disease: evidence from enhanced depth imaging spectral domain optical coherence tomography. *J Alzheimers Dis* 2014;40:907–17.
- [20] Bulut M, Yaman A, Erol MK, Kurtuluş F, Toslak D, Doğan B, et al. Choroidal thickness in patients with mild cognitive impairment and Alzheimer's type dementia. *J Ophthalmol* 2016;2016:7291257.
- [21] Bayhan HA, Aslan Bayhan S, Celikbilek A, Tanik N, Gürdal C. Evaluation of the chorioretinal thickness changes in Alzheimer's disease using spectral-domain optical coherence tomography. *Clin Exp Ophthalmol* 2015;43:145–51.
- [22] Cunha JP, Moura-Coelho N, Proença RP, Dias-Santos A, Ferreira J, Louro C, et al. Alzheimer's disease: a review of its visual system neuropathology. Optical coherence tomography—a potential role as a study tool in vivo. *Graefes Arch Clin Exp Ophthalmol* 2016;254:2079–92.
- [23] Spaide RF, Koizumi H, Pozzoni MC, Pozzoni MC. Enhanced depth imaging spectral-domain optical coherence tomography. *Am J Ophthalmol* 2008;146:496–500.
- [24] Ramrattan RS, van der Schaft TL, Mooy CM, de Bruijn WC, Mulder PG, de Jong PT. Morphometric analysis of Bruch's membrane, the choriocapillaris, and the choroid in aging. *Invest Ophthalmol Vis Sci* 1994;35:2857–64.
- [25] Wakatsuki Y, Shinojima A, Kawamura A, Yuzawa M. Correlation of aging and segmental choroidal thickness measurement using swept source optical coherence tomography in healthy eyes. *PLoS One* 2015;10:e0144156.
- [26] Shin JW, Shin YU, Lee BR. Choroidal thickness and volume mapping by a six radial scan protocol on spectral-domain optical coherence tomography. *Ophthalmology* 2011;119:1017–23.
- [27] Ding X, Li J, Zeng J, Ma W, Liu R, Li T, et al. Choroidal thickness in healthy Chinese subjects. *Invest Ophthalmol Vis Sci* 2011;52:9555–60.
- [28] Zhang L, Lee K, Niemeijer M, Mullins RF, Sonka M, Abr MD. Automated segmentation of the choroid from clinical SD-OCT. *Invest Ophthalmol Vis Sci* 2016;53:7510–9.
- [29] Chen Q, Fan W, Niu S, Shi J, Shen H, Yuan S. Automated choroid segmentation based on gradual intensity distance in HD-OCT images. *Opt Express* 2015;23:8974–94.
- [30] Esmaelpour M, Ansari-Shahrezaei S, Glittenberg C, Nemetz S, Kraus MF, Hornegger J, et al. Choroid, Haller's, and Sattler's layer thickness in intermediate age-related macular degeneration with and without fellow neovascular eyes. *Invest Ophthalmol Vis Sci* 2014;55:5074–80.
- [31] Agawa T, Miura M, Ikuno Y. Choroidal thickness measurement in healthy Japanese subjects by three-dimensional high-penetration optical coherence tomography. *Graefes Arch Clin Exp Ophthalmol* 2011;249:1485–92.
- [32] Barteselli G, Chhablani J, El-emam S, Wang H, Chuang J, Kozak I, et al. Choroidal volume variations with age, axial length, and sex in healthy subjects: a three-dimensional analysis. *Ophthalmology* 2012;119:2572–8.
- [33] Chakraborty R, Read SA, Collins MJ. Diurnal variations in axial length, choroidal thickness, intraocular pressure, and ocular biometrics. *Invest Ophthalmol Vis Sci* 2011;52:5121–9.
- [34] Usui S, Ikuno Y, Akiba M, Maruko I, Sekiryu T, Nishida K, et al. Circadian changes in subfoveal choroidal thickness and the relationship with circulatory factors in healthy subjects. *Invest Ophthalmol Vis Sci* 2012;53:2300–7.
- [35] Choi W, Mohler KJ, Potsaid B, Lu CD, Liu JJ, Jayaraman V, et al. Choriocapillaris and choroidal microvasculature imaging with ultrahigh speed OCT angiography. *PLoS One* 2013;8:e81499.
- [36] Williams MA, McGowan AJ, Cardwell CR, Cheung CY, Craig D, Passmore P, et al. Retinal microvascular network attenuation in Alzheimer's disease. *Alzheimers Dement (Amst)* 2015;1:229–35.
- [37] Cheung CY, Ting Y, Ikram MK, Ong SY, Li X, Hilal S, et al. Microvascular network alterations in the retina of patients with Alzheimer's disease. *Alzheimers Dement* 2014;10:135–42.
- [38] Tzekov R, Mullan M. Vision function abnormalities in Alzheimer disease. *Surv Ophthalmol* 2014;59:414–33.
- [39] Shao L, Xu L, Chen CX, Yang LH, Du KF, Wang S, et al. Reproducibility of subfoveal choroidal thickness measurements with enhanced depth imaging by spectral-domain optical coherence tomography. *Invest Ophthalmol Vis Sci* 2013;54:230–3.